

## REVIEW

---

# Management of Duodenal Perforation Post-Endoscopic Retrograde Cholangiopancreatography. When and Whom to Operate and What Factors Determine The Outcome? A Review Article

Norman Oneil Machado

Department of Surgery, Sultan Qaboos University Hospital. Muscat, Oman

### ABSTRACT

**Context** Endoscopic retrograde cholangiopancreatography (ERCP) has evolved from a diagnostic tool to primarily therapeutic procedure. With this, the complexity of the procedure and risk of complication including duodenal perforation have increased. In this article, the recent literature is reviewed to identify the optimal management and factors influencing the clinical outcome. **Method** Recent literature in English language from the year 2000 onwards, containing major studies of 9 or more cases on duodenal perforation post ERCP were analyzed. **Results** Literature review revealed a total of 251 cases of duodenal perforation reported in 10 major reports presenting 9 or more cases each. The mean age of these patients was 58.5 years with nearly two third (62.9%) being female patients. The predominant location of the perforation was: duodenal wall (34.5%), perivaterian (31.3%), common bile duct (23.0%), and unknown in 7.9%. Early diagnosis within 24 hours was made in 78.5%, with 55.8% of these being diagnosed during or immediately after ERCP. CT scan was the most useful investigations in detecting perforations missed during ERCP (44.6%). Conservative management was employed in 62.2%, which was successful in 92.9% of these cases. Ten of these who failed conservative management required salvage surgery (6.4%) and one died of pneumothorax (0.6%). The predominant surgical intervention was closure of perforation (49.0%) with or without other procedures, retroperitoneal drainage (39.0%), duodenal exclusion (24.0%) and common bile duct exploration and T tube insertion (13.0%). The overall mortality was 8.0% which appears to be better than previously reported (16-18%). Among the 20 patients who died, six (30.0%) had salvage surgery, five (25.0%) had delay in diagnosis/intervention beyond 3 days and 3 (15.0%) required multiple operations. **Conclusion** While the patients with duodenal perforation invariably require surgical intervention, most of the patients with perivaterian injuries can be successfully managed conservatively. The most important factors for recent better outcome were early detection and prompt treatment. Delay in diagnosis and intervention, salvage surgery after failed conservative management, multiple operations, and older age group contributed significantly to the poor outcome.

### INTRODUCTION

Endoscopic retrograde cholangiopancreatography (ERCP) is an important diagnostic and therapeutic modality for various pancreatic and biliary problems [1, 2, 3]. Sphincterotomy is carried out in addition, mainly to remove biliary stones, to drain the biliary tree and to facilitate placement of stents in the common bile duct and pancreatic duct [1, 2, 3]. Despite the well established safety of the procedure, there is still risk of complications such as pancreatitis, perforation and bleeding. The incidence of major complications range from 5.4% to 23.0% and the overall mortality from 0.1 to 1% [1, 2, 3]. However, delay in the diagnosis and

intervention following duodenal perforation, leads to significantly higher mortality (8-23%) as a consequence of sepsis and multiorgan failure [4, 5, 6, 7, 8, 9, 10, 11, 12, 13, 14, 15]. Traditionally traumatic and non-traumatic duodenal perforation have been managed surgically. However, in the past decade the management has evolved towards a selective approach [6, 7, 10, 11, 12, 13]. ERCP induced perforation may be retroperitoneal (typically in the periampullary region due to sphincterotomy or guidewire usage) or intraperitoneal (typically in the lateral wall and endoscopy related) [4, 5, 10, 12, 15, 16]. While the patient with scope induced perforation would need surgical intervention, the first 2 groups could generally be managed conservatively as they tend to be smaller in size and are usually well contained [4, 5, 6, 7, 8, 9, 10, 11, 12, 13, 14, 15]. Because of the rarity of the complication, no consensus exists on management guidelines and selection criteria for surgery or conservative management. Recommendations have been based on anecdotes and small case series. Although perforation as a result of ERCP is rare, the

Received July 7<sup>th</sup>, 2011 - Accepted December 2<sup>nd</sup>, 2011

**Key words** Ampulla of Vater; Cholangiopancreatography, Endoscopic Retrograde; Intestinal Perforation; Stents

**Correspondence** Norman Oneil Machado

Department of Surgery; Sultan Qaboos University Hospital; PO Box 38, Al-Khod 123; Muscat; Sultanate of Oman

Phone: +968-2441.3851; Fax: +968-2441.3851

E-mail: oneilnorman@gmail.com

**Table 1.** Literature review (2000 to 2011): demographic details.

ID	Series	No. of cases	Frequency <sup>a</sup> (%)	Age (years): mean (range)	Sex (male:female)
#1	Krishna <i>et al.</i> , 2011 [6]	14	NR	46 (11-68)	8:6
#2	Morgan <i>et al.</i> , 2009 [10]	24	0.2	62 (NR)	9:15
#3	Avgerinos <i>et al.</i> , 2009 [8]	15	0.34	69 (34-87)	6:9
#4	Mao <i>et al.</i> , 2008 [9]	9	0.37	58 (36-71)	3:6
#5	Knudson <i>et al.</i> , 2008 [14]	32	0.6	56 (52-60)	7:25
#6	Fatima <i>et al.</i> , 2007 [13]	75	0.8	56 (14-91)	23:52
#7	Assalia <i>et al.</i> , 2007 [13]	22	NR	63.8 (57-71)	10:12
#8	Wu <i>et al.</i> , 2006 [11]	28	0.45	67 (43-86)	15:13
#9	Preetha <i>et al.</i> , 2003 [15]	18	0.45	72.5 (48-82)	7:11
#10	Stapfer <i>et al.</i> , 2000 [4]	14	1	48.5 (NR)	4:10
<b>Total</b>	-	<b>251</b>	<b>0.2-1</b>	<b>58.5 (11-91)</b>	<b>93:158</b> <b>37.1:62.9%</b>

<sup>a</sup> Frequency of duodenal perforation per number of ERCP performed  
NR: not reported

potentially serious nature of these complications mandate better understanding of the factors predisposing to this complication and the most appropriate management strategies. The recent literature is reviewed here, and the indication and nature of surgery and factors influencing the outcome is analyzed.

## LITERATURE REVIEW

A review of recent literature from Jan 2000 to May 2011 was carried by searching PubMed/MEDLINE database using terms ERCP, endoscopic retrograde cholangiopancreatography and duodenal perforation. Only studies in English literature containing more than 9 cases and which were well documented were analyzed.

## STATISTICS

Frequencies were used as descriptive statistics and the Fisher's exact test was applied by means of the SPSS (Version 13.0 for Windows; SPSS Inc., Chicago, IL, USA) statistical package. A two-tailed P value less than 0.05 was chosen as statistically significant.

## RESULTS

### Literature Review

Review of recent English literature between 2000 and 2011 revealed a total of 251 cases of duodenal perforation reported in 10 major reports with 9 or more cases (Table 1). The mean age of these patients was 58.5 years with nearly two third (n=158, 62.9%) being female patients. The perforation was as a consequence of sphincterotomy in 65 cases (25.9%), guide wire insertion in 54 cases (21.5%), endoscope related in 36 cases (14.3%), stent placement in 20 cases (8.0%) and unknown in 20 cases (8.0%). The predominant location of the perforation was: duodenal wall (87 cases, 34.5%), perivaterian (79 cases, 31.3%), common bile duct (58 cases, 23.0%), and unknown in 20 cases (7.9%). Early diagnosis within 24 hours was made in 197 cases (78.5%) with 140 cases diagnosed during or immediately after ERCP (55.8%) (Table 2). CT scan

was the most useful investigation in diagnosing patients with perforation not detected during ERCP (112 cases, 44.6%; Table 3). Table 4 shows that conservative management was employed in 156 cases (62.2%) and was successful in 145 cases (92.9%). Among the 11 patients, where conservative treatment failed, 10 (6.4%) required salvage surgery and one (0.6%) died of pneumothorax. The predominant surgical intervention was closure of perforation (49 cases, 49.0%) with or without other procedures, retroperitoneal drainage (39 cases, 39.0%), duodenal exclusion (24 cases, 24.0%) and common bile duct T tube insertion (13 cases, 13.0%). The overall mortality was 8.0% (20 cases), which appears to be better than that previously reported (16-18%) [4]. Six (30.0%) of these 20 patients who died had salvage surgery, five (25.0%) had delay in diagnosis and intervention beyond 3 days, and 3 (15.0%) required multiple operations.

## DISCUSSION

With the emergence of newer diagnostic imaging technologies, ERCP is evolving into a predominately therapeutic procedure. The indications for ERCP with sphincterotomy are often for choledocholithiasis and stenting the common bile duct in unresectable malignant biliary obstruction [1, 2, 3]. However, the major concern is the morbidity and mortality associated with it, particularly in those with duodenal perforation. The risk factors for perforation include: 1) patient related factors: suspected sphincter of Oddi dysfunction, female sex, older age, normal bilirubin levels, previous history of post ERCP pancreatitis, abnormal or distorted anatomy as in situs inversus or post Billroth II gastrectomy; or 2) technique related factors: difficult cannulation, pancreatic duct contrast injection, longer duration of procedure, sphincterotomy and precut technique (particularly if incision goes beyond the usual recommended sector between 11 and 1 "O'clock" position), balloon sphincter dilatation and procedure performed by lesser experienced endoscopist [1, 4, 5, 7, 8, 10, 13, 15].

**Table 2.** Literature review (2000 to 2011): clinical details.

ID	Predisposing procedure	Site of perforation	Early presentation (<24 h)	Late presentation (>24 h)	Delay in treatment (days): mean (range)
#1	Endoscope related: 11 (78.6%) Guidewire related: 2 (14.3%) Sphincterotomy: 1 (7.1%)	Duodenum: 12 (85.7%) Common bile duct: 2 (14.3%)	10 (71.4%)	4 (28.6%)	6.6 (1-18)
#2	Manometry and sphincterotomy: 9 (37.5%) Dilatation and stenting: 3 (12.5%) Guidewire related: 2 (8.3%) Endoscopic mucosal resection: 1 (4.2%) Not reported: 9 (37.5%)	Duodenum and common bile duct: 12 (50.0%) Perivaterian: 12 (50.0%)	20 (83.3%) 16 immediately (within hrs)	4 (17.7%) (3 to 5 days)	3.5 (2-5)
#3	Guidewire related: 10 (66.7%) Diagnostic: 5 (33.3%)	Duodenum: 9 (60.0%) Perivaterian: 3 (20.0%) Retroperitoneal air only: 1 (6.7%) Unknown: 2 (13.3%)	11 (73.3%) 10 immediately (within hrs)	4 (26.7%) (3-42 days)	12.2
#4	Precut related: 6 (66.7%) Sphincterotomy: 1 (11.1%) Precut and sphincterotomy: 1 (11.1%) Basket related: 1 (11.1%)	Perivaterian: 7 (77.8%) Common bile duct: 2 (22.2%)	9 (100%) 8 immediately (within hrs)	0	<1 day
#5	Sphincterotomy: 22 (68.8%) Stent placement: 10 (31.3%)	Perivaterian: 13 (39.4%) Duodenum: 10 (30.3%) Miscellaneous: 5 (15.2%) Unknown: 5 (15.2%) <sup>b</sup>	27 (84.4%)	5 (15.6%)	NR (1-8)
#6	Guidewire related: 24 (32.0%) Sphincterotomy: 11 (14.7%) Endoscope related: 8 (10.7%) Common bile duct cannulation: 8 (10.7%) Stent placement: 7 (9.3%) Stricture dilatation: 5 (6.7%) Difficult stone extraction: 1 (1.3%) Unknown: 11 (14.7%)	Duodenum: 34 Common bile duct: 34 Pancreatic duct: 1 Unknown: 6	66 (88.0%) 53 immediately (within hrs)	9 (12.0%)	<2 days
#7	Sphincterotomy: 17 (77.3%) Guidewire related: 2 (9.1%) Endoscope related: 2 (9.1%) Unknown: 1 (4.5%)	Duodenum: 2 (9.1%) Perivaterian: 20 (90.9%)	20 (90.9%)	2 (9.1%)	<2 days
#8	Guidewire related: 7 (25.0%) Endoscope related: 3 (10.7%) Miscellaneous: 2 (7.1%) Unknown: 7 (25.0%) Not reported: 9 (32.1%)	Duodenum: 3 (10.7%) Perivaterian: 11 (39.3%) Common bile duct: 7 (25.0%) Unknown: 7 (25.0%)	14 (50.0%)	14 (50.0%)	>2 days
#9	Sphincterotomy: 7 (38.9%) Endoscope related: 6 (33.3%) Guidewire related: 4 (22.2%) Unknown: 1 (5.6%)	Duodenum: 6 (33.3%) Perivaterian: 7 (38.9%) Common bile duct: 4 (22.2%) Retroperitoneal air only: 1 (5.6%)	8 (44.4%)	10 (55.6%)	<2 days
#10	Sphincterotomy: 6 (42.9%) Endoscope related: 5 (35.7%) Guidewire related: 3 (21.4%)	Duodenum: 5 (35.7%) Perivaterian: 6 (42.9%) Common bile duct: 3 (21.4%)	12 (85.7%) 11 immediately (within hrs)	2 (14.3%)	5 (3-7)
<b>Total</b>	<b>Sphincterotomy: 65 (25.9%)<sup>a</sup></b> <b>Guidewire related: 54 (21.5%)</b> <b>Endoscope related: 36 (14.3%)</b> <b>Stent placement: 20 (8.0%)</b> <b>Manometry and sphincterotomy: 9 (3.6%)</b> <b>Common bile duct cannulation: 8 (3.2%)</b> <b>Precut: 6 (2.4%)<sup>a</sup></b> <b>Stricture dilatation: 5 (2.0%)</b> <b>Others: 10 (4.0%)</b> <b>Unknown: 20 (8.0%)</b> <b>Not reported: 18 (7.2%)</b>	<b>Duodenum: 87 (34.5%)<sup>c</sup></b> <b>Perivaterian: 79 (31.3%)</b> <b>Common bile duct: 58 (23.0%)<sup>c</sup></b> <b>Retroperitoneal air only: 2 (0.8%)</b> <b>Unknown: 20 (7.9%)</b> <b>Miscellaneous: 6 (2.4%)<sup>b</sup></b>	<b>197 (78.5%)</b> <b>140 (55.8%) during ERCP</b>	<b>54 (21.5%)</b>	<b>2.5 (1-18)</b>

<sup>a</sup> In addition, one patient of study #4 had two procedures (precut followed by sphincterotomy) and was classified into the "Others" procedure group

<sup>b</sup> The sum of study #5 totals to 33 though original article quotes it as 32

<sup>c</sup> The cases of study #2 were equally distributed between duodenum and common bile duct  
NR: not reported

In view of the therapeutic and prognostic implications of duodenal perforation, a classification of ERCP related perforation was prudent. In 1999 Howard *et al.* classified ERCP related perforation into 3 distinct groups: group I, guide wire perforation; group II,

periampullary perforation; and group III, duodenal perforation remote from papilla [5]. A further classification which is more often used now was proposed by Stapfer *et al.* based on the mechanism, anatomical location and severity of injury which may

**Table 3.** Literature review (2000 to 2011): investigations.

ID	Abdomen X-ray	Abdomen US	CT scan	Contrast study	During ERCP <sup>a</sup>
#1	3 (21.4%)	12 (85.7%)	11 (78.6%)	3 (21.4%)	0
#2	1 (4.2%)	NR	6 (25.0%)	0	16 (66.7%)
#3	1 (6.7%)	0	11 (73.3%)	0	4 (26.7%)
#4	8 (88.9%)	0	8 (88.9%)	0	8 (88.9%)
#5	10 (31.3%)	0	11 (34.4%)	0	11 (34.4%)
#6	10 (13.3%)	0	27 (36.0%)	19 (25.3%)	26 (34.7%)
#7	13 (59.1%)	0	19 (86.4%)	8 (36.4%)	2 (9.1%)
#8	6 (21.4%)	0	9 (32.1%)	7 (25.0%)	8 (28.6%)
#9	3 (16.7%)	0	10 (55.6%)	2 (11.1%)	5 (27.8%)
#10	3 (21.4%)	0	0	4 (28.6%)	11 (78.6%)
<b>Total</b>	<b>58 (23.1%)</b>	<b>12 (4.8%)</b>	<b>112 (44.6%)</b>	<b>41 (17.1%)</b>	<b>89 (36.3%)</b>

<sup>a</sup> Detection of duodenal perforation at the time of ERCP

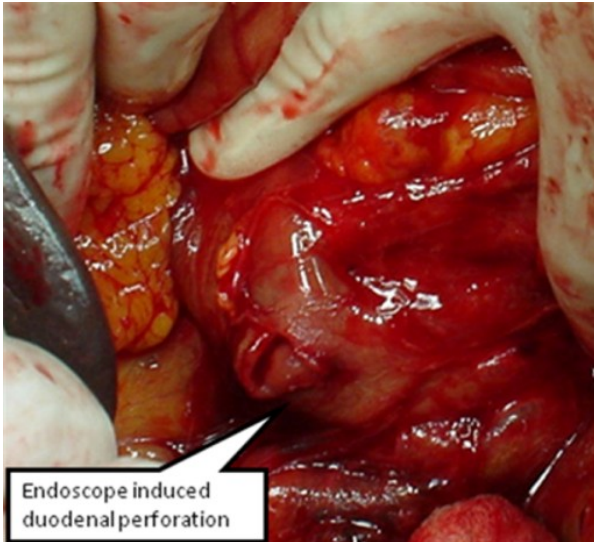
NR: not reported

predict the need for surgery [4]. The ERCP related perforation was classified in descending order of severity into four types: type I, lateral or medial wall duodenal perforation (Figure 1); type II perivaterian injuries (Figure 2); type III distal bile duct injuries

related to wire/basket instrumentation (Figure 3) and type IV retroperitoneal air alone. Type IV however was not considered to be true perforation and was believed to be related to compressed air used to maintain patency of the duodenal lumen which resulted in air

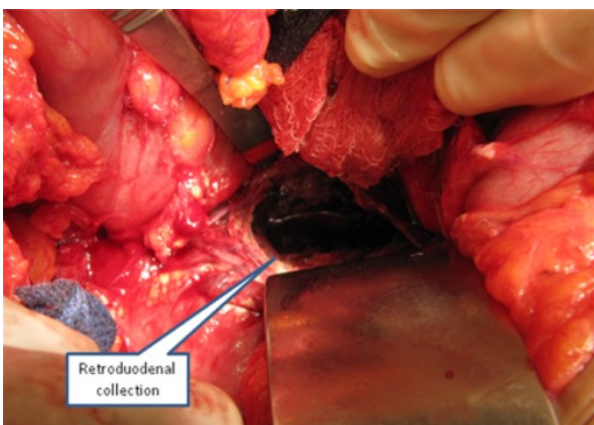**Table 4.** Literature review (2000 to 2011): management and outcome.

ID	Conservative management	Surgical management	Surgical procedure	Outcome: mortality
#1	7 (50.0%) Percutaneous ultrasound guided drainage: 7 (100%)	7 (50.0%)	Closure of perforation: 2 T tube insertion: 5 Choledocholithotomy: 4 Duodenal exclusion: 2 Tube duodenostomy: 1 Gastrojejunostomy: 3 Retroperitoneal drainage: 3	1 (7.1%)
#2	14 (58.3%)	10 (41.7%)	Closure of perforation / retroperitoneal drainage: 9 Retroperitoneal drainage only: 1 Closure of perforation / retroperitoneal drainage / gastrojejunostomy: 1	1 (4.2%)
#3	2 (13.3%)	13 (86.7%)	Closure of perforation / duodenal exclusion / gastrojejunostomy: 12 Closure of perforation / choledochoduodenostomy: 1 Retroperitoneal drainage: 1	3 (20.0%)
#4	6 (66.7%)	3 (33.3%)	Retroperitoneal drainage: 3 T tube insertion: 2	0
#5	20 (62.5%)	12 (37.5%)	Closure of perforation: 3 Retroperitoneal drainage: 5 T tube insertion: 2 Duodenal exclusion: 1 Tube duodenostomy: 1	0
#6	53 (70.7%) Salvage surgery: 4 (7.5%)	22 (29.3%)	Closure of perforation: 12 Retroperitoneal drainage: 7 Choledochojejunostomy / biliary reconstruction: 3	5 (6.7%)
#7	20 (90.9%) Salvage surgery: 2 (10.0%)	4 (18.2%)	Closure of perforation: 3 T tube insertion: 2 Retroperitoneal drainage: 2 Choledochojejunostomy / biliary reconstruction: 2	1 (4.5%)
#8	18 (64.3%)	10 (35.7%)	Closure of perforation: 2 Retroperitoneal drainage: 6 T tube insertion: 3	4 (14.3%)
#9	8 (44.4%)	10 (55.6%)	Closure of perforation: 5 Duodenal exclusion: 5	3 (16.7%)
#10	8 (57.1%) Salvage surgery: 3 (37.5%)	9 (64.3%)	Duodenal exclusion / gastrojejunostomy / retroperitoneal drainage: 4 Choledocholithotomy / T tube insertion: 3 Duodenogastrectomy: 1	2 (14.3%)
<b>Total</b>	<b>156 (62.2%)</b> <b>Salvage surgery: 9 (5.8%)</b>	<b>100 (39.8%)</b> <b>Included salvage surgery</b>	<b>Closure of perforation: 49 (49.0%)</b> <b>Retroperitoneal drainage: 39 (39.0%)</b> <b>Duodenal exclusion: 24 (24.0%)</b> <b>T tube insertion: 13 (13.0%)</b>	<b>20 (8.0%)</b>



**Figure 1.** Lateral wall duodenal perforation. Patient was explored four hours following perforation which was managed with primary closure.

going within the layer of duodenal wall as in pneumatosis cystoides or outside the lumen [4, 5, 8, 11, 13]. This post procedural retroperitoneal air is a common benign finding after endoscopic sphincterotomy and had no predictive value in identifying patients who requires intervention [4, 7, 8, 9, 10, 11, 12, 13]. This was supported by the finding of 13 to 29% incidence of inconsequential retroperitoneal air in several prospective studies [17, 18]. Sphincterotomy induced and guidewire induced perforation constitute the majority (up to 80%) and rarely need intervention [1, 2, 3, 4, 7, 10, 13]. The less often occurring lateral duodenal wall perforation is likely to be associated in patients with altered gastrointestinal anatomy undergoing ERCP. The presence of prior pancreaticoduodenectomy, Billroth II gastrectomy or situs inversus or duodenal diverticulum increases the difficulty of navigating the side viewing endoscope through an atypical path with changed points of fixation [18, 19, 20]. These patients are at increased risk of traumatic injury particularly from bowing of the endoscope. Techniques have been

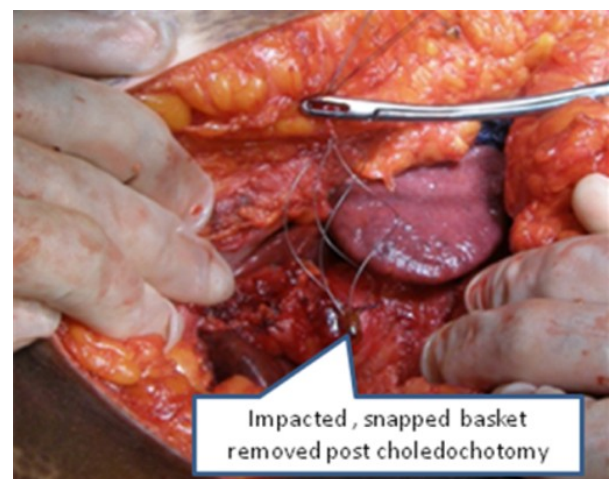


**Figure 2.** Retroduodenal collection of infected fluid explored three days after type II perforation.

described by authors to improve success of ERCP in these patients with altered foregut anatomy including double balloon enteroscopy or rigid overtubes, but with continued increased morbidity [20, 21]. The anatomy in these patients predisposes them to a pattern of injury that required operative repair.

Duodenal perforations are difficult to diagnose during the ERCP procedure because they occur in the lateral wall of the duodenum by side view endoscope [8]. Also the routine use of sedation during the procedure makes the diagnosis even more difficult because it masks the symptoms [4, 8, 10]. However, recently several reports indicate the identification of perforation by direct vision when carefully looked for or by documenting contrast extravasation [10, 13, 14]. Careful inspection for this complication during ERCP is warranted should the procedure be therapeutic or technically demanding due to various factors. These include when dilatation is carried out or in patients with local anatomic variations [4, 7, 10, 14, 19]. Specific signs and symptoms suspicious of perforation are epigastric pain and back pain (more intense than usual), tenderness with or without peritoneal signs (generally rebound tenderness), surgical emphysema, tachycardia and fever, although the last two findings tend to be late [4, 5, 8, 10, 14]. Tachycardia is a more constant physical finding but it may not be a reliable indicator because it can be caused by other factors including pain. The presence of leukocytosis and fever are often seen 12 hours or more after completion of ERCP. Signs of peritonitis usually develop after several hours when the duodenal contents extravasate into the peritoneal cavity [11, 12, 13].

Early diagnosis and prompt treatment of duodenal perforation post ERCP, is the essence for better outcome. The index of suspicion should be high, in those patients with undue pain and fever, post procedure. In such patients with suspicion of perforation, prompt diagnosis and institution of systemic antibiotics and intravenous fluid resuscitation is mandatory [5, 6, 7, 8, 9, 10, 11, 12, 13, 14, 15]. The most useful diagnostic measure in them is



**Figure 3.** Removal of impacted, snapped Dormia basket. Type III perforation that resulted was managed by T-tube insertion.

radiographic. An urgent plain X-ray abdomen would reveal free intraperitoneal air, extraluminal retroperitoneal air or contrast [7, 8, 10, 13, 22]. CT scan of the abdomen and pelvis with oral contrast is the most sensitive and specific diagnostic modality to evaluate for the presence of perforation [7, 8, 10, 13, 22]. CT scan can effectively demonstrate retroperitoneal or intraperitoneal air and fluid or extravasation of oral contrast [7, 8, 14, 22]. In general, free intraperitoneal air implies an uncontained leak that is likely to require surgical intervention, whereas isolated retroperitoneal air is suggestive of a sphincterotomy site perforation [6, 8, 14, 22]. However, the amount of air may not correlate with the size of perforation but rather with the degree of endoscopic insufflation of air during the procedure [7, 8, 9, 10]. Retroperitoneal or intraperitoneal fluid without air is more suggestive of acute pancreatitis than perforation which almost always results in extraluminal gas attributable to insufflations [10, 11]. If patients with significant retroperitoneal air and fluid are managed non operatively, then the fluid collection is monitored by repeated imaging as persistent infected fluid collection can lead to non healing of the perforation site. The persistent large fluid collection may then require image guided or surgical drainage [6, 8, 10, 13].

After the initial resuscitation and establishment of diagnosis of duodenal perforation, the first objective in the management would be to determine whether the patient could be managed conservatively or would require surgical intervention. This is determined by the patient's condition, mechanism of injury, site and degree of leak [4, 5, 6, 7, 8, 9, 10, 11, 12, 13, 14, 15]. Unfortunately, it may not always be possible to determine the site and mechanism of perforation despite several investigations [13, 14]. However these patients then, irrespective of method of treatment would need an effective nasobiliary and gastrointestinal drainage to decrease the leak of digestive juice that would otherwise gradually accumulate in the retroperitoneal space. Historically, ERCP related perforation was managed surgically [13]. The indication of surgery include type I injury, generalized peritonitis not amenable to percutaneous drainage, major contrast leak, documentation of ERCP perforation with choledocholithiasis or retained hardware (Dormia basket), massive subcutaneous emphysema and failure of non surgical treatment [4, 6, 8, 10, 13, 23]. The goals in the surgical management of ERCP related perforation include: 1) to control the sepsis (drainage of the retroperitoneal, intra-abdomen collection and drainage of the biliary system, removal of bile duct stones or retained basket; and 2) to repair the perforation with or without diversion. In the last decade management has shifted towards selective approach [4, 5, 6, 7, 8, 9, 10, 11, 12, 13, 14, 15].

The site and mechanism of injury guides to the management approach [5, 7, 8, 10, 13, 15]. Type I injury (duodenal perforation) will require surgical intervention [5, 7, 10, 15]. The perforations are closed

primarily in one or two layers following debridement of devitalized tissue. Perforations less than 1 cm who present early are treated easily with primary repair [4, 6, 7, 10, 13]. The closure is performed transversely to ensure a patent duodenal lumen. For slightly larger duodenal perforation, jejunal serosal patch is an option, which can be used to close the duodenal wall. However, repair of perforation when large or when delayed is fraught with danger. The huge volume of fluid (nearly 6 liters of fluid including saliva, gastric and pancreaticobiliary juice) that traverse the duodenum daily will lead to high output fistula in the event of dehiscence of duodenal repair, a likely possibility when the wall is edematous and friable [4, 7, 8, 10, 12]. As a result, duodenal diversion is usually reserved for high risk patients with delay in diagnosis or larger defects in duodenal wall. This achieves the objective of diverting the gastrointestinal contents and the proteolytic enzymes from the duodenal repair site and in case of duodenal fistula facilitates management by having a controlled fistula.

Duodenal diversion technique includes tube decompression, duodenal diverticulation and pyloric exclusion [4, 5, 6, 7, 8, 9, 10, 11, 12, 13, 14]. The use of tube decompression in the management of duodenal repair however is controversial. Its drawbacks include new perforation being made in the gastrointestinal tract and inefficiency of the duodenostomy/jejunostomy tube in decompressing the duodenum properly. Another method of complete diversion is performing duodenal diverticulation which includes a distal Billroth II gastrectomy, closure of duodenal wound, placement of a decompressive catheter into the duodenum and generous drainage of the duodenal repair [4, 6, 7, 8, 10, 13]. Truncal vagotomy and biliary drainage may also be added. The major shortcoming of duodenal diverticulosis is that it is an extensive procedure which is inappropriate for hemodynamically unstable patients. Pyloric exclusion is an alternative to above extensive procedure. This procedure consists of duodenal wound repair, closure of the pylorus through a gastrostomy with running suture or by stapling and side to side gastrojejunostomy at the site of gastrostomy [6, 7, 8, 9, 10, 11, 12, 13]. In the majority of patients the closure of pylorus breaks down after several weeks and gastrointestinal continuity re-establishes. The advantage is that the procedure is less extensive, less time consuming and causes less physiological disturbances. Most clinician advocate pyloric exclusion procedure if duodenal diversion is needed [7, 10, 11, 12, 13].

The type II and III perforation caused by guidewire or basket instrumentation tend to be small and well contained and are likely to heal spontaneously and hence are usually managed by non operative method [4, 7, 8, 10, 13, 24, 25]. Those in favor of conservative management also note that there is often insignificant finding or inability to identify the perforation site during exploration as noted in 7.9% of the patients in the literature review [13, 14]. However, management



of periamпуляр perforation in general remains controversial [24, 25]. There are some who advocate immediate endoscopic treatment once the retroperitoneal perforation is identified [7, 8, 9, 10, 11, 12, 13]. This constitutes of diversion of bile and pancreatic secretion away from the site of perforation using either an internal biliary stent or a nasobiliary stent [11, 12, 13]. The alternative is biliary decompression with percutaneous transhepatic biliary drainage. Follow-up contrast scan helps to detect the development and progress of retroperitoneal abdominal collection which may require percutaneous or surgical drainage. The indications for surgery in type II and III injuries include failure of non surgical management, large free or retroperitoneal collection, ongoing leakage, prominent peritoneal signs or suspected suppuration [4, 6, 7, 10, 11, 12, 13]. The surgical options include direct closure of the perforation and retroperitoneal drainage with or without duodenal diversion [4, 6, 8, 9, 10, 11, 12, 13]. Periamпуляр perforations have also been successfully repaired by performing sphincteroplasty using a minimal transverse duodenotomy [26]. The factors that are likely to indicate an operative intervention were analyzed by Fatima *et al.* who observed that on univariate analysis, mean age ( $65\pm 4$  years for operative vs.  $55\pm 2$  years for conservative;  $P=0.02$ ), higher ASA (equal to, or greater than, 3;  $P=0.003$ ), patients with duodenal perforation ( $P<0.001$ ) and patients with increasing technical difficulty (grade) of the procedure (near to the significant level:  $P=0.06$ ) were the important factors [13]. On applying multivariate logistic regression model, the association of ASA state and site of perforation were significant factors ( $P=0.01$  and  $P=0.003$ , respectively) [13]. Using a 4 point scoring system, assigning 1 point each for the presence of fever, tachycardia, guarding on examination and leukocytosis, Knudson *et al.* observed that 83% who required surgical intervention had a score of 3 or 4 and those managed conservatively scored 0 to 1 [14]. The odds ratio in this clinical index for requiring operative management in patients with a score greater than or equal to 3 was 40 ( $P<0.01$ ) [14].

The conservative approach when employed includes nil per mouth, nasogastric or nasoduodenal tube decompression, broad spectrum antibiotics and frequent re-evaluation [4, 7, 10, 13, 24, 25]. The conservative approach which is most often tried in these patients with type II and III perforation is likely to be successful in 50% to 90% of the cases [4, 5, 6, 7, 8, 9, 10, 11, 12, 13, 14, 15, 16]. Based on these growing data in the literature, it has become clear that many of these patients can be treated nonsurgically [4, 5, 6, 7, 8, 9, 10, 11, 12, 13, 14, 15, 16]; however, the main challenge continues to be in distinguishing patients who could be treated non-operatively from those who require early surgery. This is specially so as some of these patients managed conservatively and fail to respond, would then require salvage surgery and are found to fare badly following the surgery both in terms

of morbidity and mortality as was noted in the literature review [4, 8, 10, 12, 13].

Several novel methods of managing ERCP induced perforation have been reported [27, 28]. Some patients have been managed successfully with an endoclipping device [27]. However, this would require caution as adequate closure requires inclusion of submucosal layer of the bowel wall, which clips do not reliably ensure. These patients need to be carefully selected and the method is applicable in small well defined perforations, detected without delay and having met all the criteria for conservative management such as the absence of abdominal signs and collections. Recent report also presents the successful endoscopic closure of lateral duodenal perforation using fibrin glue [28].

## CONCLUSIONS

Duodenal perforation post ERCP is uncommon but has grave consequences if not adequately and promptly treated. The clinical features of abdominal pain, fever and leukocytosis after ERCP especially after a prolonged and difficult procedure and the radiographic features of retroduodenal air with fluid would indicate the diagnosis. The mechanism, site and extent of injury suggested by clinical and radiographic features would guide towards a selective approach of conservative or surgical management. In patients who require surgical intervention, the interval between the perforation and operation is of great significance as mortality increases dramatically in the event of delay. The optimal operation for ERCP induced duodenal perforation appears to be primary repair and duodenal diversion with gastrojejunostomy and pyloric exclusion. However, if the perforation is noted and managed early, primary repair without diversion has similar results, provided the peritoneal contamination is minimal. While patients with type I perforation would invariably require immediate surgical intervention, those with type II or III may often be managed conservatively. However, they would require constant observation supported by radiological investigation to confirm satisfactory progress failing which they may require surgical intervention. Delay in diagnosis and intervention, salvage surgery after failed conservative management, multiple operations and older age group contributed significantly to the poor outcome. The outcome in recent years however, has significantly improved due to early detection and appropriate management strategies.

---

**Conflict of interest** The authors have no potential conflict of interest

---

## References

1. Christensen M, Matzen P, Schulze S, Rosenber J. Complications of ERCP: a prospective study. *Gastrointest Endosc.* 2004;60(5):721-31.
2. Freeman ML, Nelson DB, Sherman S, Haber GB, Herman ME, Dorsher PJ et al. Complications of endoscopic biliary sphincterotomy. *N Engl J Med.* 1996;335(13):909-18.

3. Masci, Toti G, Mariani A, Curioni S, Lomazzi A, Dinelli M, Minoli G. Major early complications of diagnostic and therapeutic ERCP: a prospective multicenter study. *Am j Gastroenterol.* 2001;96(2):417-23.
4. Stapfer M, Selby RR, Stain SC, Katkhouda N, Parekh D, Jabbour N et al. Management of duodenal perforation after endoscopic retrograde cholangiopancreatography and sphincterotomy. *Am Surg.*2000;232:191-8.
5. Howard TJ, Tan T, Lehman GA, Sherman S, Madura JA, Fogel E et al. Classification and management of perforations complicating endoscopic sphincterotomy. *Surgery.*1999;126(4):658-63.
6. Krishna RP, Singh RK, Behari A, Kumar A, Saxena R, Kapoor VK. Post endoscopic retrograde cholangiopancreatography perforation managed by surgery or percutaneous drainage. *Surg Today.*2011;41:660-6.
7. Lai CH, Lau WY. Management of endoscopic retrograde cholangiopancreatography related perforation. *Review. Surg.*2008;6(1):45-8.
8. Avgerinos DV, Liaguna OH, Lo AY, Voli J, Leitman IM. Management of endoscopic retrograde cholangiopancreatography related duodenal perforations. *Surg Endosc.*2009;23(4):833-38.
9. Mao Z, Zhu Q, Wu W, Wang M, Li J, Lu A et al. Duodenal perforation after endoscopic retrograde cholangiopancreatography. Experience and management. *J Laproendosc Adv Surg Tech.*2008;18(5):691-5.
10. Morgan KA, Fontenot BB, Ruddy JM, Mickey S, Adams DB. Endoscopic retrograde cholangiopancreatography gut perforations: when to wait! When to operate!. *Am Surg.*2009;75(6):477-83.
11. Wu HM, Dixon E, May GR, Sutherland FR. Management of perforation after endoscopic retrograde cholangiopancreatography (ERCP): a population based review. *HPB(Oxford).*2006;8(5):393-9.
12. Assalia A, Suissa A, Ilivitzki A, Mahajna A, Yassin K, Hashmonai M, et al. Validity of clinical criteria in the management of endoscopic retrograde cholangiopancreatography related duodenal perforations. *Arch Surg.*2007.142(11):1059-64.
13. Fatima J, Baron TH, Topazian MD, Houghton SG, Iqbal CW, Ott BJ et al. Pancreaticobiliary and duodenal perforations after perampullary endoscopic procedures. Diagnosis and management. *Arch Surg.*2007;142(5):448-55.
14. Knudson K, Raeburn CD, McIntyre RC Jr, Shah RJ, Chen YK, Brown WR et al. Management of duodenal and pancreaticobiliary perforations associated with perampullary endoscopic procedures. *Am J Surg.*2008;196(6):975-81.
15. Preetha M, Chung YF, Chan WH, Ong HS, Chow PK, Wong WK et al. Surgical management of endoscopic retrograde cholangiopancreatography-related perforations. *ANZJ Surg.*2003; 73(12):1011-4.
16. Scarlett PY, Falk GL. The management of perforation of the duodenum following endoscopic sphincterotomy. A proposal for selective therapy. *ANZJ Surg.*1994;64(12):843-6.
17. Genzlinger JL, McPhee MS, Fisher JK, Jacob KM, Helzberg JH. Significance of retroperitoneal air after endoscopic retrograde cholangiopancreatography with sphincterotomy. *Am J Gastroenterol.*1999;94(5):1267-7.
18. de Vries JH, Duijm LE, Dekker W, Guit GL, Ferwerda J, Scholten ET. CT before and after ERCP. Detection of pancreatic pseudotumor, asymptomatic retroperitoneal perforation and duodenal diverticulum. *Gastrointest Endosc.*1997;45(3):231-5.
19. Enns R, Eloubeidi MA, Mergener K, Jowell PS, Branch MS, Pappas TM et al. ERCP related perforations: risk factors and management. *Endoscopy.*2002;34(4):293-8.
20. Emmett DS, Mallat DB. Double balloon ERCP in patients who have undergone Roux-en-Y surgery. a case series. *Gastrointest Endosc.*2007;66(5):1038-41.
21. Pai RD, Carr-Locke DL, Thompson CC. Endoscopic evaluation of the defunctionalised stomach by using shapeLock technology. *Gastrointest Endosc.* 2007;66:578-81.
22. Zissin R, Shapiro-Feinberg M, Oscadchy A, Pomeranz I, Leichtmann G, Novis B et al. Retroperitoneal perforation during endoscopic sphincterotomy: Imaging findings. *Abdom Imaging.*2000;25(3):279-82.
23. Cottan PB, Lehman G, Vennes J, Geenen JE, Russell RC, Meyers WC et al. Endoscopic sphincterotomy complications and their management . an attempt at consensus. *Gastroenterol Endosc.*1991;37:383-93.
24. Chung RS, Sivak MV, Ferguson DR. Surgical decision in the management of duodenal perforation complicating endoscopic sphincterotomy. *Am J Surg.*1993;165:700-3.
25. Kaneko T, Akamatsu T, Shimodaira K, Ueno T, Gotoh A, Mukawa K et al. Non surgical treatment of duodenal perforation by endoscopic repair using a clipping device. *Gastrointest Endosc.*1999;50:410-3.
26. Sarli L, Porrini C, Costi R, Regina G, Violi V, Ferro M, Roncoroni L. Operative treatment of perampullary retroperitoneal perforation complicating endoscopic sphincterotomy. *Surgery.*2007;142(1):26-32.
27. Baron TH, Gostout CJ, Herman L. Hemoclip repair of a sphincterotomy induced duodenal perforation. *Gastrointest Endosc.*2000;52(4):566-68.
28. Mutignani M, Iacopini F, Dokas S, Larghi a, Familiari P, Tringoli A et al. Successful endoscopic closure of a lateral duodenal wall perforation at ERCP with fibrin glue. *Gastrointest Endosc.*2006;63(4):725-27.